

Correction of Complex Foot Deformities Using the Ilizarov External Fixator

Mehmet Kocaoğlu, MD, Levent Eralp, MD, Ata Can Atalar, MD, and F. Erkal Bilen, MD

There are many drawbacks to using conventional approaches to the treatment of complex foot deformities, like the increased risk of neurovascular injury, soft-tissue injury, and the shortening of the foot. An alternative approach that can eliminate these problems is the Ilizarov method. In the current study, a total of 23 deformed feet in 22 patients were treated using the Ilizarov method. The etiologic factors were burn contracture, poliomyelitis, neglected and relapsed clubfoot, trauma, gun shot injury, meningitis, and leg-length discrepancy (LLD). The average age of the patients was 18.2 (5–50) years. The mean duration of fixator application was 5.1 (2–14) months. We performed corrections without an osteotomy in nine feet and with an osteotomy in 14 feet. Additional bony corrective procedures included three tibial and one femoral osteotomies for lengthening and deformity correction, and one tibiotalar arthrodesis in five separate extremities. At the time of fixator removal, a plantigrade foot was achieved in 21 of the 23 feet by pressure mat analysis. Compared to preoperative status, gait was subjectively improved in all patients. Follow-up time from surgery averaged 25 months (13–38). Pin-tract problems were observed in all cases. Other complications were toe contractures in two feet, metatarsophalangeal subluxation from flexor tendon contractures in one foot, incomplete osteotomy in one foot, residual deformity in two feet, and recurrence of deformity in one foot. Our results indicate that the Ilizarov method is an effective alternative means of correcting complex foot deformities, especially in feet that previously have undergone surgery. (The Journal of Foot & Ankle Surgery 41(1):30–39, 2002)

Key words: complex foot deformity, ilizarov method, osteotomy

Complex foot deformity can be described as a foot with multiplanar deformities with or without shortening of the foot. It can also define those feet with poor soft-tissue coverage and relapsed or neglected cases, which can be all complicated by other problems, such as leg-length discrepancy, lower leg deformity, osteomyelitis, and nonunion. Such deformities are caused by trauma, neglected or relapsed clubfoot, poliomyelitis, osteomyelitis, burn contracture, and neuromuscular disease, among others.

Traditionally, correction of complex foot deformities has been managed through extensive soft-tissue releases, osteotomies, or arthrodesis. Conventional techniques tend to have many disadvantages, including neurovascular injury, soft-tissue problems, and a shortened foot. Moreover, the management of complex foot deformities that have undergone one or more surgical procedures is difficult (1, 2).

The Ilizarov method was chosen for the correction of complex foot deformities because it enables correction in

all three orthogonal planes, at a rate of which may be tailored to the type and degree of deformity. It causes minimal surgical morbidity without the shortening of the foot, and allows the surgeon to manipulate the rate and direction of the correction (3, 4). The purpose of this study was to evaluate the results of surgical management with Ilizarov technique of complex foot deformities, performed at our institution over the last 4 years.

Material and Methods

Twenty-three deformed feet in 22 patients, with an average age of 18.2 (5–50) years, were treated with the Ilizarov method (Table 1). Historical data were recorded for each patient. All patients received preoperative evaluation of both lower extremities. This evaluation consisted of range-of-motion measurements, neurovascular assessment, standing footprints, two plane and posterior tangential radiographs, orthoroentgenography, computed tomography (CT) and 3D reconstruction, photography, and Doppler ultrasonography. The talus–first metatarsal angle and calcaneal pitch angle were measured on a lateral weightbearing film (5). A posterior tangential x-ray was obtained to visualize the body of the calcaneus. Plantar sensation was carefully assessed. Doppler ultrasonography was performed in cases of burn contracture and previous surgical interventions for vascular evaluation.

From Department of Orthopaedics and Traumatology, Istanbul University, Istanbul School of Medicine, Istanbul, Turkey. Address correspondence to: Mehmet Kocaoğlu, MD, Department of Orthopaedics and Traumatology, Istanbul University, Istanbul School of Medicine, 34390 Çapa-Istanbul, Turkey; e-mail: kocaoylum@superonline.com.

Received for publication November 16, 2000; accepted in revised form for publication September 13, 2001.

The Journal of Foot & Ankle Surgery 1067-2516/02/4101-0030\$4.00/0 Copyright © 2002 by the American College of Foot and Ankle Surgeons

TABLE 1 Etiology, operative procedures, and follow-up of all patients

Case	Age	Sex	Localization	Foot deformity	Additional deformity	Etiology	Osteotomy type	Additional corrective procedures	Previous surgery (number)	External fixator time (months)	Immobilization in orthotics or cast (month)	Complications	Secondary procedures	Result (foot)	Follow-up period (months)
1	27	F	L	Equinus	-	Polio	Midfoot	Tibiotalar arthrodesis	-	7		Incomplete osteotomy	Re-osteotomy	P	27
2	24	M	R	Pes calcaneus	LLD	Polio	V-osteotomy	Tibial osteotomy	-	10				RD	18
3	22	F	L	PEV	-	Polio	-	Achilles tendon lengthening	-	14				P	36
4	6	M	L	PEV	-	Clubfoot	-	-	-	3	6	Recurrence		R	14
5	7	F	L	PEV	-	Meningitis sequela	-	-	-	5	5			P	21
6	6	F	R	PEV	-	Neglected clubfoot	Midfoot	-	-	5		Toe contracture + 2nd MP subluxation	Flexor tendon lengthening	RD	32
7	13	F	R	PEV	-	Relapsed clubfoot	Midfoot	-	2	5				P	24
8	7	M	R	PEV	-	Trauma	-	-	-	3.5				P	38
9	6	M	L	Pes planovalgus	Metatarsus adductus	Burn contracture	Midfoot	-	-	2	5			P	16
10	5	M	R	Pes planovalgus	Metatarsus adductus	Burn contracture	Midfoot	-	-	2.5				P	30
11	50	F	R	Pes planovalgus	-	Burn contracture	Midfoot	-	-	7			Bursectomy	P	27
12	15	F	R	PEV	-	Clubfoot	-	-	3	3				P	17
13	30	F	L	Equinus	LLD	Gun shot injury	Supramalleolar	Tibial osteotomy	1	5				P	24
14	37	M	L	Pes planovalgus	-	Trauma	U-osteotomy	-	-	2				P	31
15	16	M	L	PEV	LLD	Polio	Supramalleolar	Tibial osteotomy	-	4				P	26
16	28	M	L	Pes planovalgus	-	Trauma	Supramalleolar	-	-	8				P	19
17	27	M	L	Forefoot equinus	-	LLD	Midfoot	Femoral osteotomy	-	4				P	25
18	30	M	R	Pes calcaneovalgus	-	LLD	Supramalleolar	-	-	8				P	13
19	5	M	R	PEV	-	Neglected clubfoot	-	-	-	8	3	Toe contracture	Flexor tendon lengthening	P	35
20	18	M	L	Equinus	-	Trauma	-	-	-	3				P	27
21	6	M	Bil	PEV	-	Bilateral relapsed clubfoot	-	Bilateral Achilles tendon lengthening	2	3	R:6 L:0			P	30
22	16	M	R	PEV	-	Trauma	Supramalleolar	-	1	8				P	20

PEV, Pes equinovarus; LLD, leg-length discrepancy; P, plantigrade; RD, residual deformity.

Four basic osteotomy patterns were utilized to correct foot deformities:

1. Supramalleolar osteotomy (Fig. 1) was used in patients with deformity at the level of a previous ankle arthrodesis and deformities at the level of the talus or subtalar joint in the presence of ankle ankylosis.
2. V-osteotomy is a double osteotomy, where the anterior part of the osteotomy starts from the neck of talus and passes through anterior part of the calcaneus. The posterior part is performed between the dorsum of the calcaneal tuberosity and plantar surface of the foot. These two osteotomies produce a V-shape on the sagittal plane (3, 6). V-osteotomy produces a stiff subtalar joint; hence we preferred to use it in patients with stiff subtalar joints and in patients with neuromuscular imbalance (Fig. 2).
3. The U-osteotomy starts from neck of the talus, crosses the subtalar joint, and extends to the superior aspect of the tuberosity of the calcaneus. Like the V-osteotomy, a triangular middle bone segment is created within the bodies of the talus and calcaneus. This mobile bone segment was stabilized with one or two K-wires, and connected to the lower ring of the base frame, to enable correction of the anterior and posterior segment in relation to the middle segment. The U-osteotomy also required a normal relationship between hindfoot and forefoot (4, 6, 7). If the U-osteotomy is opened medially or laterally, varus or valgus deformities of foot can be corrected. Additionally, the foot height also can be increased (Fig. 3).
4. Midfoot osteotomy, which consists of the anterior part of the V-osteotomy and a tarsal osteotomy, is used in patients with forefoot deformities (Fig. 4).

Other corrective procedures were also carried out. In selected patients, tibial and femoral osteotomies for leg-length discrepancy, Achilles tendon lengthening, temporary fixation of the metatarsophalangeal joint with K-wire, bursectomies and ankle arthrodeses were performed (Table 1). Tarsal tunnel decompression was used in two feet treated with U- and V-osteotomies.

Surgical Method

In all cases, surgery was carried out under general anesthesia without neuromuscular blockage or muscle relaxants. Epidural anesthesia was also used in 19 patients as a postoperative analgesic and as an aid to rehabilitation. A radiolucent operating room table and image intensifier were used in all cases. Tarsal tunnel decompression was simultaneously combined with U- and V-osteotomies in order to protect the posterior tibial nerve.

The frame consisted of three parts: 1) the base frame, which is placed on the leg; 2) the heel frame; and 3) the forefoot frame. The base frame is comprised of two rings that fix the tibia with a single K-wire and a single Schanz pin from each ring (T-configuration). The square heel frame made of carbon fiber is preferred to the half ring. Two crossed olive wires, or one K-wire combined with a Schanz pin going through the longitudinal axis of the calcaneus, on the heel frame and two parallel olive wires going through the first and fifth, and under the second, third, and fourth metatarsal heads on the carbon fiber forefoot frame were used. Additionally, one or two wires were used in the mobile bone segment created with U- and V-osteotomies. A lateral incision and osteotome were used for the U-osteotomy. The gigli saw was used for the anterior part of the V-osteotomy and for other midfoot osteotomies. Correction was started on the 2nd postoperative day to prevent premature consolidation. The goal of the distraction procedure was to obtain a 1 mm/day opening at the osteotomy site.

Fixator duration depended on deformity types and choice of treatment (e.g., with or without osteotomy). If osteotomy was performed, the fixator was removed after obtaining consolidation at the distraction site. Otherwise, the fixator was removed 6 weeks after the deformity correction. In the latter case, patients were protected with a cast or another form of orthotic for an additional 3–6 months to prevent recurrence of deformity.

Postoperative patient evaluation consisted of measurement of range of motion, radiologic assessment with anterior-posterior, lateral, and posterior tangential planes, orthoroentgenography in patients whose limbs were lengthened, and standing footprints.

Results

Of the 22 patients, 14 were male and 8 were female. The etiology of the deformities varied to include burn contracture (3), poliomyelitis (4), neglected and relapsed clubfoot (7), trauma (5), gun shot injury (1), equinus deformity secondary to leg-length discrepancy (2), and meningitis sequela (1). Six of 23 feet had undergone previous surgical intervention. Two of seven clubfeet were cases of neglected foot. The remaining five clubfeet had not responded to prior surgical treatment.

Correction was achieved without osteotomy method in nine feet (Fig. 5) and with one of these osteotomies in 14 feet. Osteotomy types and number of cases were as follows: U- (1) and V-shaped (1), midfoot (7), and supramalleolar osteotomies (5).

The mean follow-up period from surgery averaged 25 (13–38) months. The correction period varied from 3 to 10 weeks. The mean fixator duration was 5.1 (2–14) months. Hardware failure did not occur in

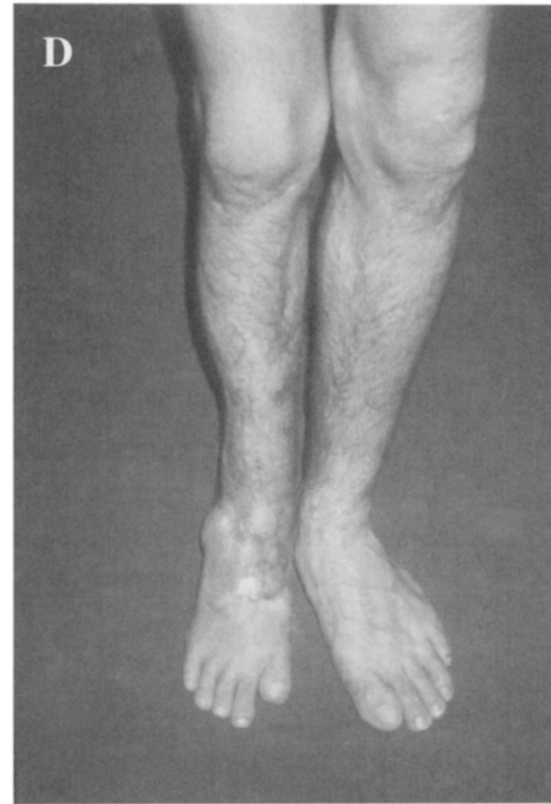
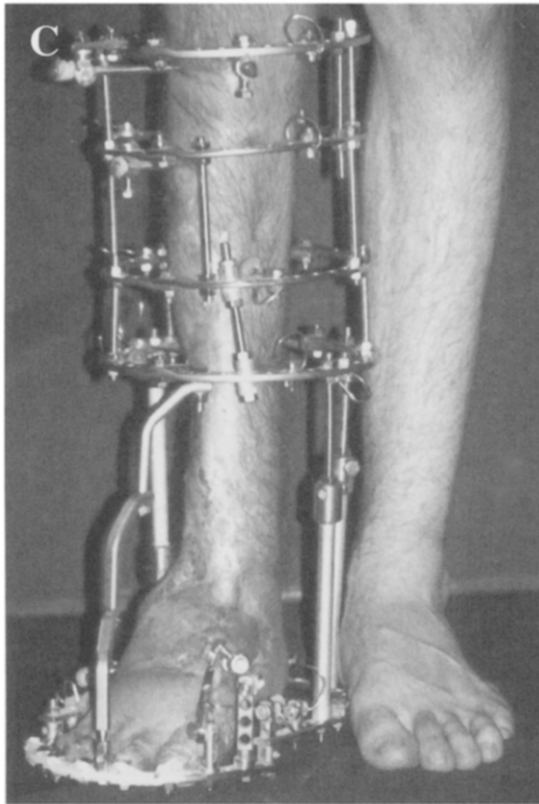
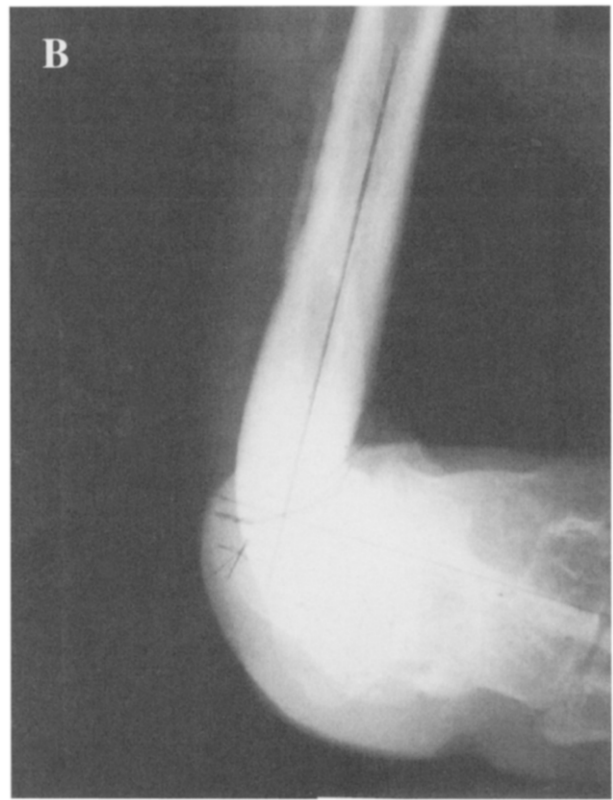
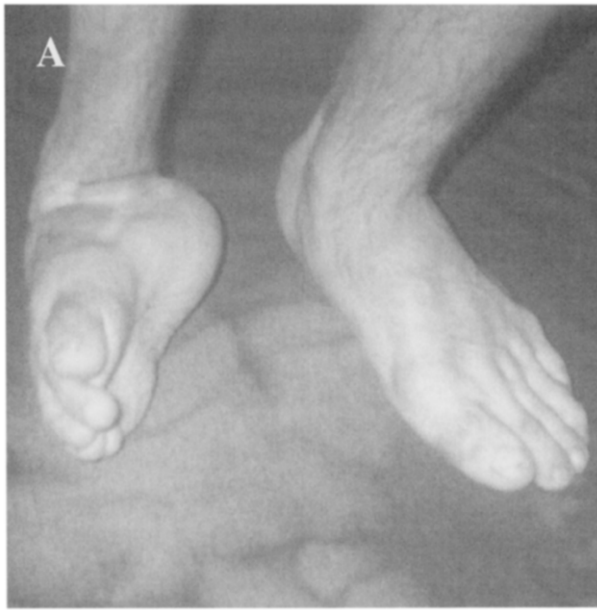
FIGURE 1 Patient No. 22 — post-traumatic pes equinovarus deformity treated with supramalleolar osteotomy. *A*, preoperative appearance of the patient; *B*, preoperative radiograph showing the proposed location of the supramalleolar osteotomy; *C*, at the end of the correction with ilizarov frame; *D*, 6 months after the fixator removal with plantigrade foot.

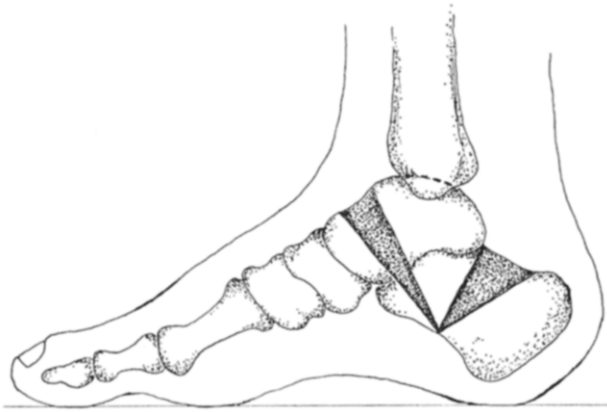


FIGURE 2 Schematic drawing of V-osteotomy.

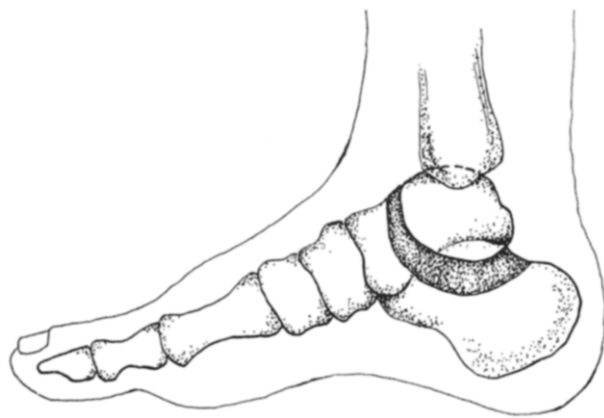


FIGURE 3 Schematic drawing of U-osteotomy.

any of the patients. Psychological intolerance requiring fixator removal was not observed. At the time of fixator removal, standing footprints revealed plantigrade foot in 21 feet, and leg-length discrepancy was eliminated in four extremities. Compared to preoperative status, gait was subjectively improved by all patients. Average ankle dorsiflexion and plantarflexion were 13.5° ($10\text{--}15^\circ$) and 47.7° ($35\text{--}50^\circ$) in all patients, except those treated with supramalleolar osteotomy. Patients treated without osteotomy ($n = 7$) were assessed radiographically. Talocalcaneal angle improved from 6.8° ($0^\circ\text{--}10^\circ$) preoperatively to 25.3° ($15^\circ\text{--}35^\circ$) postoperatively in anteroposterior plane, and from 5.6° (15° to -10°) preoperatively to 38.7° ($30^\circ\text{--}50^\circ$) postoperatively in lateral plane.

Complications were encountered in several of the feet treated: toe contractures in two patients, metatarsophalangeal joint subluxation due to flexor tendon contractures in one, incomplete osteotomy in one foot, recurrence of deformity in one foot, and residual deformity in two feet. Three secondary procedures were required in three feet in order to treat complications. Toe contractures were

treated with flexor tendon lengthening, tenotomies, and cast application under general anesthesia at the time of frame removal. Metatarsophalangeal joint subluxation due to toe contracture was treated by insertion of a K-wire following closed reduction. Re-osteotomy was performed in the one patient with incomplete osteotomy. Minor pin-tract problems on the scale of 1 and 2 according to Paley's classification (4) were observed in all cases.

Discussion

The authors defined *complex foot deformity* as a foot with multiplanar deformities and/or shortening of the foot, poor soft tissues, and cases of relapse or neglect. It may be complicated by other problems such as leg-length discrepancy, lower leg deformity, osteomyelitis, and nonunion. In conventional surgical methods, extensive soft-tissue releases, osteotomies, and arthrodeses are used in the treatment of these deformities (3). The surgical goal is maximum correction with minimal bone resection, and the establishment of a plantigrade foot. However, cases of neglected feet and feet on which multiple surgical interventions have been performed usually require wedge bone resection, which has the drawback of producing a much-shortened foot. When poor soft tissues are present, conventional open osteotomy is not possible. Scar tissue from previous surgery can complicate further surgical correction (8–10). Conventional treatment of complex foot deformities has many limitations because of the increased risk of neurovascular injury, soft-tissue injury, shortening of the foot, and destruction of collateral vascular circulation (7, 11).

Symptomatic nonunion is the most common complication of corrective arthrodesis in foot. Rates were reported from 8.1% to 26%. Devascularization of the talus, especially if large wedges are required, might produce avascular necrosis of the talus in 1–6.5% after triple arthrodesis (2). In our osteotomy series, no nonunion or avascular necrosis of talus was encountered. In conventional osteotomies, the final correction is achieved intraoperatively. The Ilizarov method, on the other hand, is amenable to adjustment during the entire treatment (3, 4, 6, 8).

The goals of foot deformity treatment should be the attainment of foot that is normal in size, pain free, plantigrade, and functional (3). There are two ways in which foot deformities can be corrected using the Ilizarov method: with and without osteotomy (4, 6, 12). In the nonosteotomy method, deformities are corrected through joints rather than the bone substance (13). Soft-tissue distraction treatment is recommended for patients who have a congruous joint with no significant fixed bony deformities and for children younger than 8 years of age (4, 6, 14, 15). Osteotomy is recommended for the

correction of fixed bony deformity in patients older than 8 years and for the correction of neuromuscular imbalance in patients where soft-tissue correction could be obtained, but the correction could not be maintained because tendon transfer is not possible (4, 6). Incidence of deformity recurrence in our cases is lower than the reported literature (4, 6, 8, 14–16). We observed only one case of deformity recurrence. This lower incidence of deformity recurrence in our cases is most likely related to following the principles regarding the use of osteotomy. Herzenberg also states that recurrence of deformity, while rare in the osteotomy treatment, is common in the nonosteotomy treatment (16).

In the constrained foot frame, forces applied to the foot are directed around the axis of a constructed hinge, positioned to correct a specifically defined deformity. In the nonconstrained system, joints of the ankle and the foot are used as the fulcrum points for correction. Application of the constrained system in the foot and ankle is technically more demanding (3, 11). Although we preferred the nonconstrained system initially, we decided

to use the constrained system foot frame, based on our experience.

Deformity at the level of a previous ankle arthrodesis and deformities at the level of the talus or subtalar joint in the presence of ankle ankylosis are treated best by a supramalleolar osteotomy (4, 6, 7). We used supramalleolar osteotomy in cases of equinovarus and calcaneovalgus deformity. V- and U-osteotomies produce a stiff subtalar joint. So we used them in patients with stiff subtalar joints and in patients with neuromuscular imbalance. The U-osteotomy requires a normal relationship between hindfoot and forefoot (4, 6, 7). We used the U-osteotomy in patients with certain types of equinus deformities. If the U-osteotomy is opened medially or laterally, varus or valgus deformities of foot can be corrected. Foot height also can be increased with the U-osteotomy. Midfoot osteotomy is used in patients with forefoot deformities (2, 4, 8). In patients in whom we wanted to prevent the development of stiff subtalar joint, we preferred to perform the midfoot osteotomy on the cuboid and navicular or more distal tarsal bones (4, 6, 7, 14).

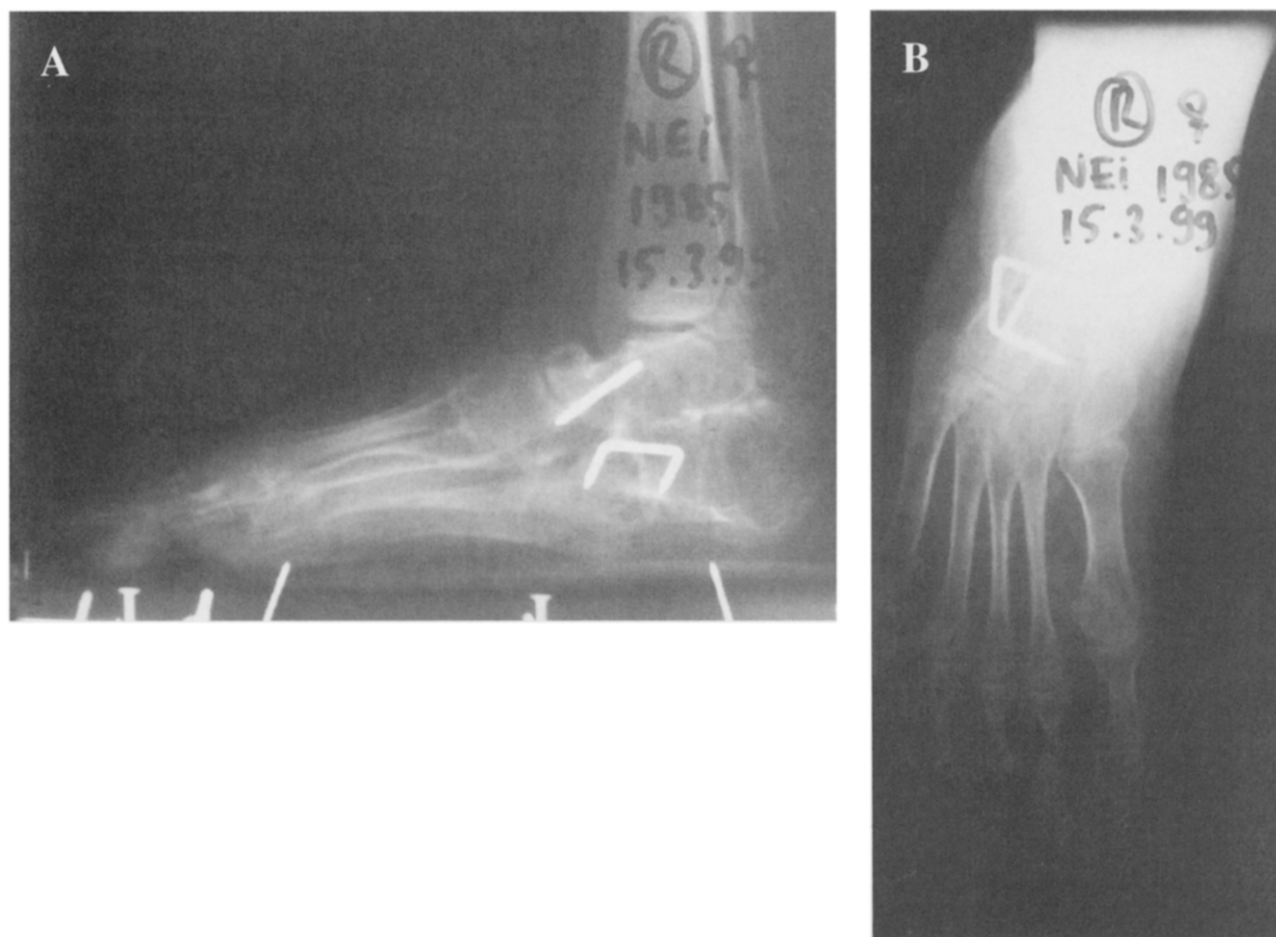


FIGURE 4 Patient No. 7 — relapsed clubfoot, with shortening and varus deformity of the foot treated with previous midfoot osteotomy. A and B, Preoperative lateral and AP radiographs.

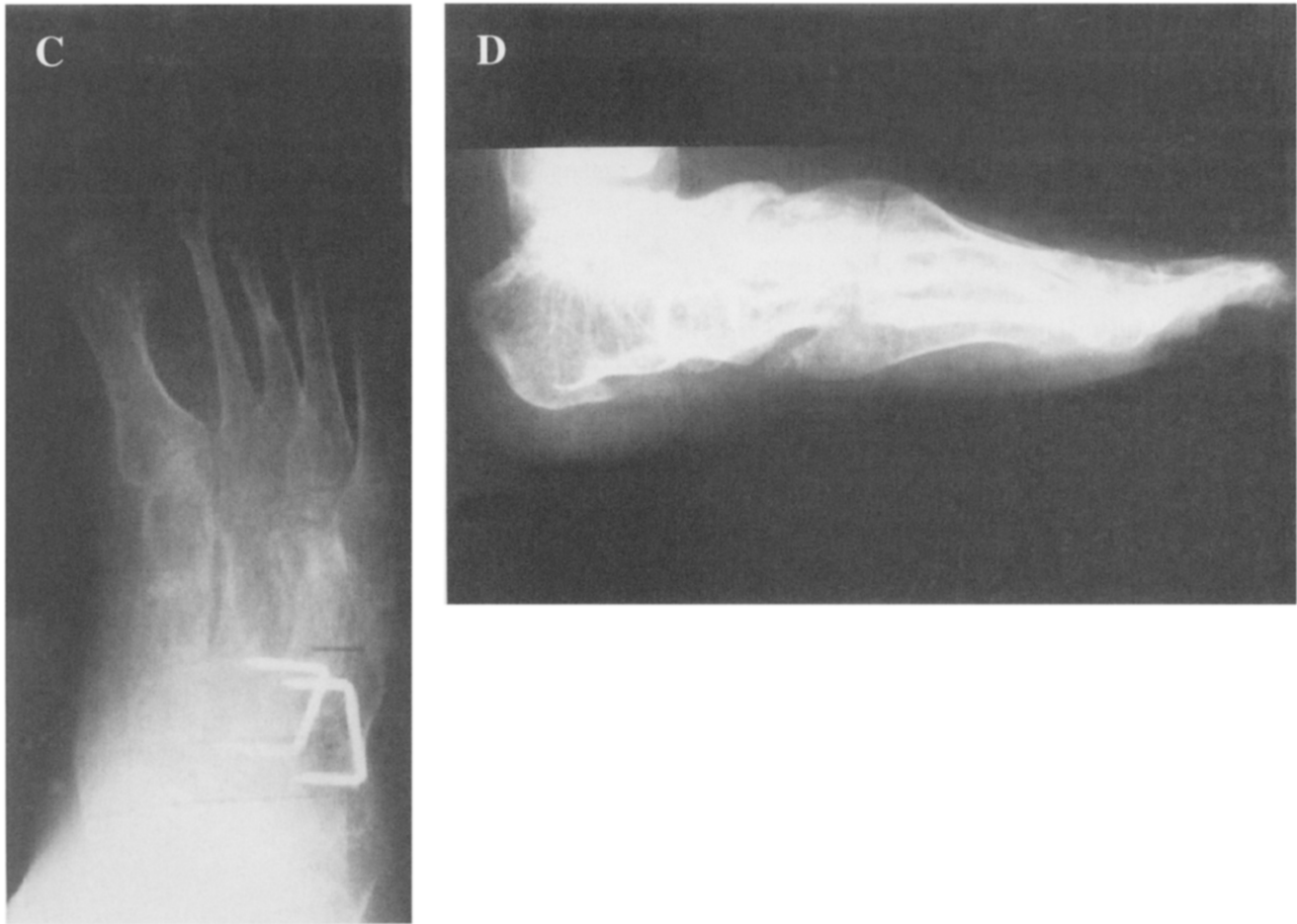


FIGURE 4 (Continued) C and D, AP and lateral radiographs 6 months after corrective surgery with osteotomy and Ilizarov method. Mature callus is obvious in the midfoot.

Toe contractures were a common problem, especially in the medial column lengthening of the foot. Prevention of toe contractures was achieved through the use of rubber slings or temporary K-wire fixation of the distal interphalangeal, proximal interphalangeal, and metatarsophalangeal joints. Paley recommends connecting a K-wire to the apparatus after inserting the wire across the base of the distal phalanx, without fixing the metatarsophalangeal joint (4, 6). We observed metatarsophalangeal joint subluxation in one case of toe contracture that had been treated by the insertion of K-wires as described by Paley. Therefore, we prefer fixing the metatarsophalangeal joint with a K-wire to prevent toe contractures, especially in cases where severe deformity is presented.

Pin-tract problems are related to skin motion at the interface and are observed mostly in the soft tissues around the long bones (4). Minor pin-tract problems were observed in all cases studied. All pin-tract problems were of grade 1 or grade 2, according to Paley's classification (4). These superficial infections

were controlled with local pin-site care. None required the extraction of the K-wire. This is probably due to less pin-skin motion in the foot compared to the soft tissue of around the long bones of the leg. Pin-site problems and toe contractures are usually related to prolonged fixator utilization and the severity of deformity.

In cases of pure foot deformity, the duration of fixator utilization depended on deformity type and choice of treatment (with or without osteotomy). In cases of foot deformity associated with other extremity problems (such as limb-length discrepancy), the duration of treatment depended on secondary procedures rather than on the foot deformity.

Paley reports the development of acute tarsal tunnel syndrome after surgery in two patients (4). In cases where U- and V-osteotomies were carried out, primary tarsal tunnel decompression was performed and no such complication was observed in any of the patients included in the present study. Early consolidation and/or incomplete osteotomy are more frequent in the foot and can be caused by an inappropriate foot frame (4, 6, 11). Early, we

observed incomplete osteotomy at the midfoot osteotomy site stemming from the surgical technique employed. In order to prevent incomplete osteotomy we used the gigli saw in midfoot osteotomies based on these experiences.

Vascular injury may occur due to surgery or secondary to deformity correction. The location of the neurovascular structures may have been altered, especially in severe burn contracture and in some complex foot deformities.

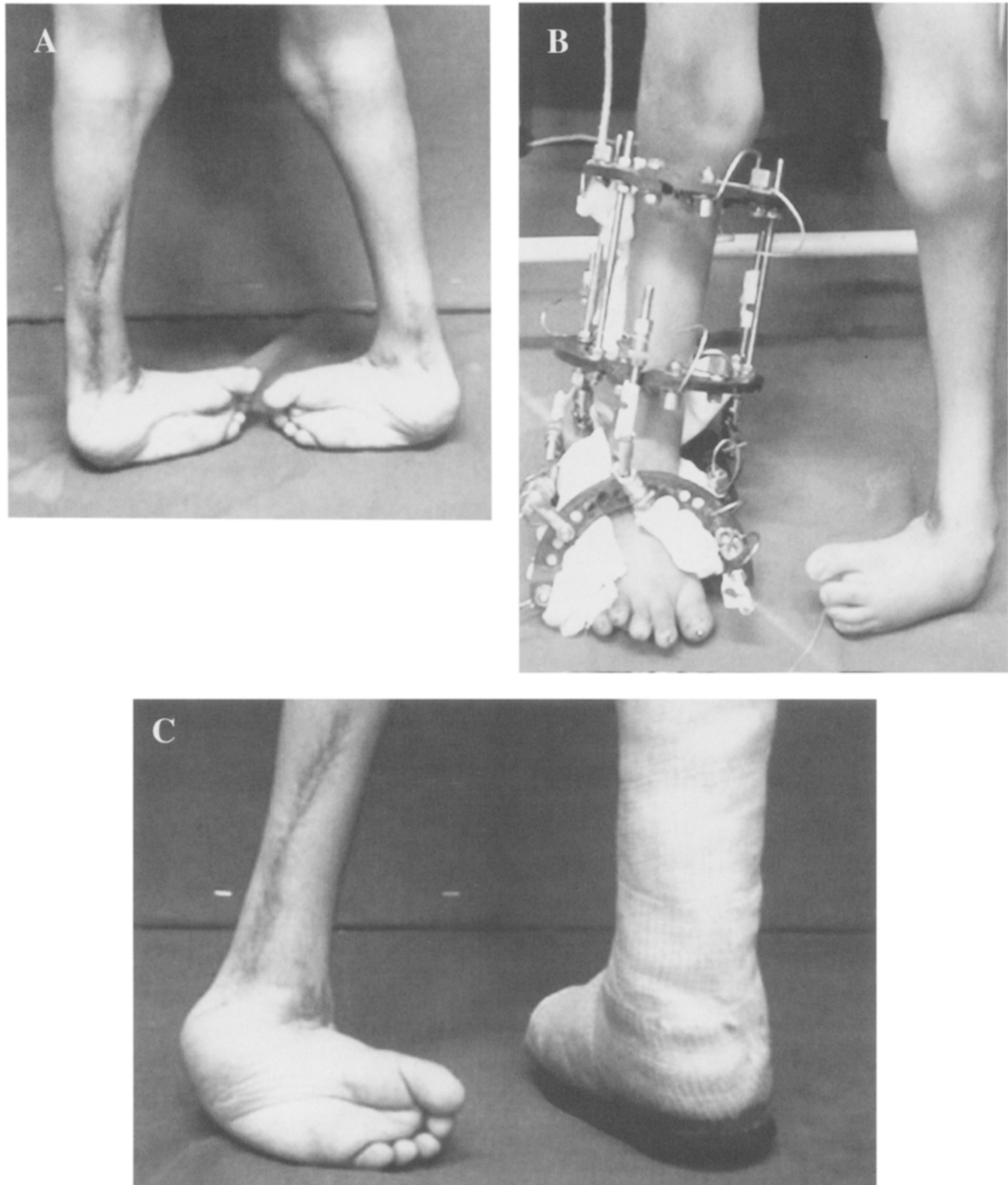


FIGURE 5 Patient No. 21 — bilateral relapsed clubfoot, treated with nonosteotomy method. A, preoperative standing appearance of the patient; B, the right side was operated on first; C, cast application was performed after fixator removal with resultant plantigrade foot.

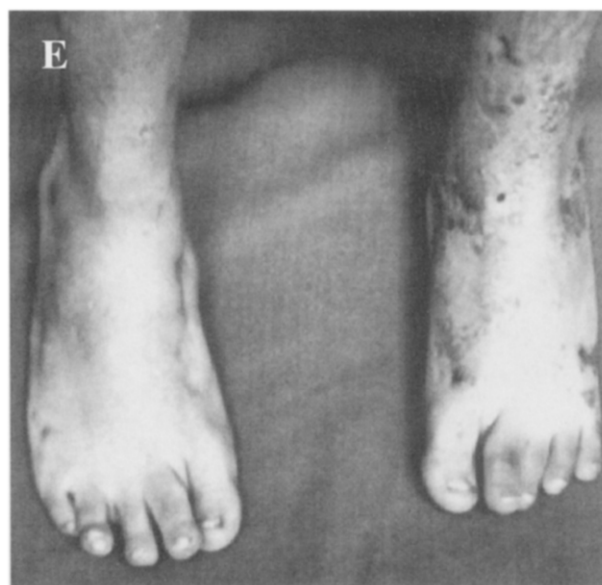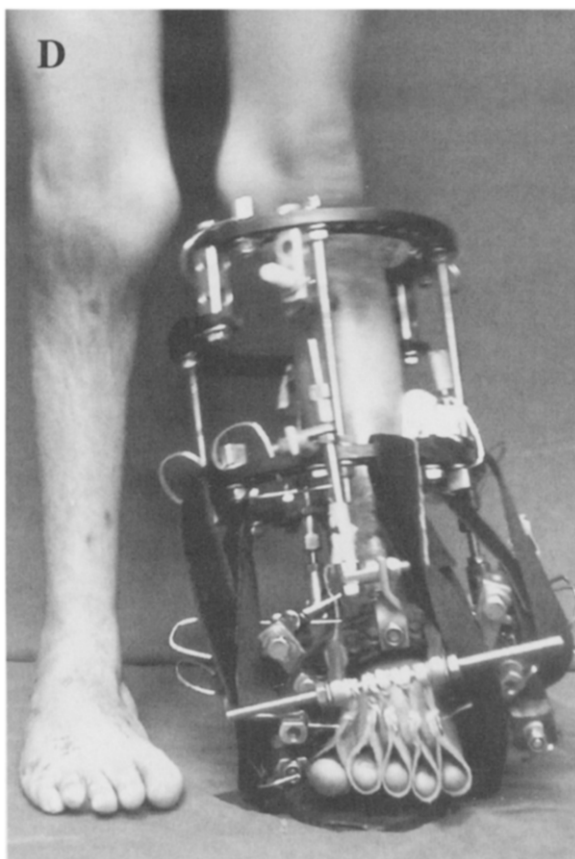


FIGURE 5 (Continued) D, left side operated on 6 months following fixator removal; E, 1 year after fixator removal of left side, patient can stand and walk with a bilateral plantigrade foot.

We performed Doppler ultrasonography in cases of prior surgical interventions. We did not observe major neurovascular injury in any of the cases included in this study.

A stiff equinovarus foot that is corrected into a plantigrade position is still a stiff plantigrade foot. Frequently, patients do not take this into consideration and may become disappointed after treatment. While aesthetically more pleasing and functionally plantigrade, the foot still does not perform normally. Therefore, before starting treatment of any complex foot deformity, it is important that the patient receives a realistic explanation of just what the foot deformity correction will accomplish, what the foot will be like in the corrected position, and the functional limitations (3).

Conclusion

Treatment of foot deformities by the Ilizarov method is technically difficult. Nonetheless, this method is particularly advantageous in treating complex foot deformities. Based on our findings, the Ilizarov method can successfully correct complex foot deformities.

References

1. Coleman, S. Equinovarus congenita, ch. 2. In *Complex Foot Deformity in Children*, pp. 23–111, edited by S. Coleman, Lea and Febiger, Philadelphia, 1983.
2. Ouzounian, T. J., Kleiger, B. Arthrodesis of foot and ankle, ch. 95. In *Disorders of the Foot and Ankle*, 2nd ed., vol. 3, pp. 2614–2646, edited by M. H. Jahss, W. B. Saunders, Philadelphia, 1992.
3. Paley, D. Principles of foot deformity corrections. In *Operative Foot Surgery*, pp. 476–514, edited by J. S. Gould, W. B. Saunders, Philadelphia, 1994.
4. Paley, D. The correction of complex foot deformities using Ilizarov's distraction osteotomies. *Clin. Orthop.* 293:97–111, 1993.
5. Rosman, M., Brown, K. Preoperative Ilizarov frame constructions for correction of ankle and foot deformities. *J. Pediatr. Orthop.* 11:238–240, 1991.
6. Paley, D. Problems, obstacles and complication of limb lengthening by the Ilizarov technique. *Clin. Orthop.* 250:81–104, 1990.
7. Bradish, C. F., Noor, S. The Ilizarov method in the management of relapsed clubfoot. *J. Bone Joint Surg.* 82-B :387–391, 2000.
8. Desgrippes Ysuelot, P., Benshel, H. Use of the Ilizarov external fixator in multioperated, recurrent clubfoot. *J. Pediatr. Orthop.* 1(B):181, 1992.
9. Calhoun, J. H., Evans, E. B., Herndon, D. N. Techniques for the management of burn contractures with the Ilizarov fixator. *Clin. Orthop.* 280:117–124, 1992.
10. Franke, J., Grill, F., Hein, G., Simon, M. Correction of clubfoot relapse using Ilizarov's apparatus in children 8–15 years old. *Arch. Orthop. Trauma Surg.* 110:33–37, 1990.

11. Grand, A. D., Atar, D., Lehman, W. B. The Ilizarov technique in correction of complex foot deformities. *Clin. Orthop.* 280:94–103, 1992.
12. Grill, F., Franke, J. The Ilizarov distractor for the correction of relapsed or neglected clubfoot. *J. Bone Joint Surg.* 69-B:593–597, 1987.
13. Reinker, K. A., Carpenter, C. T. Ilizarov applications in the paediatric foot. *J. Pediatr. Orthop.* 17:796–802, 1997.
14. Oganesian, O. V., Istomina, I. S., Kuzmin, V. I. Treatment of equinovarus deformity in adults with the use of hinged distraction apparatus. *J. Bone Joint Surg.* 78-A:546–556, 1996.
15. Oganesian, O. V., Istomina, I. S. Talipes equinovarus deformities corrected with the aid of a hinged-distraction apparatus. *Clin. Orthop.* 266:42–50, 1991.
16. Herzenberg, J. E., Paley, D. Ilizarov applications in foot and ankle surgery. *Adv. Orthop. Surg.* 16:162–174, 1992.